



DATE **CLINICAL BACKGROUND & STUDY DETAILS**

3.23.26

PATIENT

Ziggy Soto

SPECIES

Feline

BREED

DSH

SEX

MN

AGE

11.29.09

WEIGHT

11.18lbs

INTERPRETED BY

Maggie Machen Lamy,
DVM, DACVIM
(Cardiology)

HOSPITAL NAME

Everhart VH

REFERRING VET

Dr. Notarangelo

INVOICE

47251

History: Chronic grade 2/6 heart murmur. Asymptomatic. Hyperthyroidism diagnosed in November 2025, no real weight gain since diagnosis but labs have stabilized. Weight loss, intermittent vomiting but improved since thyroid treated

Pertinent abnormal PE/Chem/CBC/UA Results: fecal pending. 2/12/26: NSF except eosinophilia. 12/30/25: NSF except eosinophilia. 11/14/2025: ALT 154, T4 5.3, USG 1.020

Current medications: Methimazole Anhydrous AccuClick Transdermal Pen 60 clicks per pen (compounded) 1.25mg / click 1 dosing pen BID

Blood Pressure: 180, 170, 184 and 176mmHg.

Sedation used: Not required to complete full diagnostic ultrasound.

Pertinent previous ultrasound results: No previous.

STAT: Not requested.

Imaging performed by: Stephanie Warga RDCS, RVT.

ECHOCARDIOGRAM FINDINGS

2D, m-mode, color flow and doppler imaging is available. The left ventricular walls is borderline normal in dimensions. There is a diffusely hyperechoic endocardium consistent with fibrosis. The endocardium also appears remodeled. Papillary muscle fibrosis. The left atrium is normal. The right atrium is normal in size. The right ventricle appears normal. The mitral valve is normal in structure and mobility. Trace MR. Trace TR. Normal velocity. Blood flow through both the LVOT and RVOT are normal in velocity. Trace aortic insufficiency. No obvious cardiac tumors identified. No effusions.

CARDIAC CHART

FELINE CARDIAC PARAMETERS	BODY WEIGHT (kg)	HR (BPM)	IVSd (cm) (Moise, Pipers)	LVIDd (cm) (Moise, Pipers)	LVWd (cm) (Moise, Pipers)	FS (%)	EF (%)
NORMAL PARAMETER	-----	150-240	3.5-0.55	<2 (mean 1.5)	3.5-0.55	35-67	80-100
PATIENT	5.1	NM	0.55	1.38	0.56	46	81
FELINE CARDIAC PARAMETERS	LA/AO (Boon)	LA/AO HEART BASE (Swe) (Abbott)	LA 2D short axis Base view (cm) (Abbott)		LVOT VEL (m/s)	RVOT VEL (m/s)	E max (m/s)
NORMAL	<1.5	<1.3	<1.2		<1.6	<1.3	<0.9
PATIENT	NM	1.3	1.3		1.0	1.1	NM

Adapted from June Boon, Veterinary Echocardiography, 1998
Abbott J & MacLean H JVIM 2006;20: 111-119, Moise et al. Am J Vet Res 47:1476, 1986. Pipers et al. Am J Vet Res 40:882, 1979.

INTERPRETATION OF THE FINDINGS & FURTHER RECOMMENDATIONS

Borderline LV hypertrophy is present, which may be indicative of early hypertrophic disease or may simply represent a normal variant. Trace aortic insufficiency is also noted; however, this would not

contribute to a systolic murmur. AI in addition to borderline LVH and reportedly elevated BP readings may suggest true pathologic systemic hypertension; however, reassessment is recommended. If values are found to be persistently >180mmHg, institute Amlodipine to effect. Additionally screening for predisposing underlying causes is recommended in this geriatric cat (Cushing's, PLN, adrenal tumor, etc.), as primary disease is relatively uncommon and a rule out diagnosis.

From a structural standpoint, the cardiac changes are minimal, which would indicate clinical stability. Serial echocardiography will be necessary to determine progression. Additionally, no definitive cause is identified for the murmur in this study, making it likely physiologic in origin (i.e. secondary to tachycardia, volume changes, etc.). Given these findings, no medications are indicated.

With a normal LA dimension, there is low risk for anesthetic complication at this time. The BP should be addressed prior to proceeding, however. Additionally, any cat with this degree of fibrosis and diastolic dysfunction will be at risk for iatrogenic IV fluid overload and judicious rates are recommended. Avoid heart rate stimulating drugs unless indicated. A reasonable protocol includes opioid/benzodiazepine premedication, propofol induction, isoflurane maintenance.

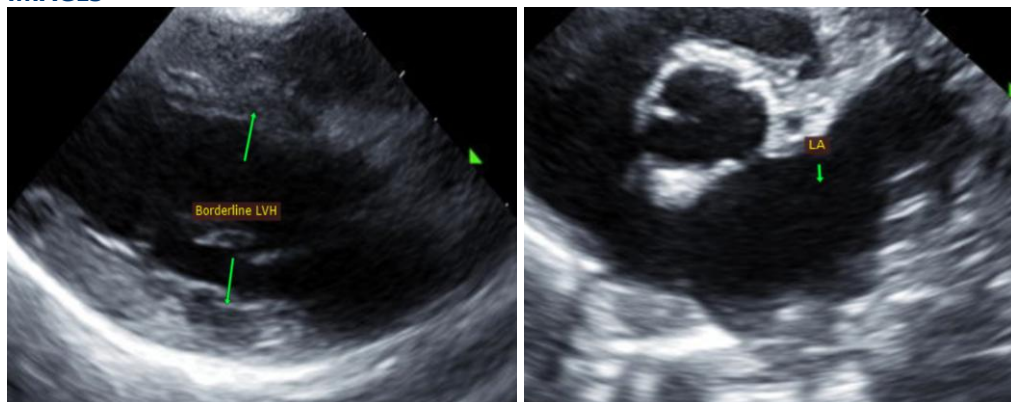
Monitor for any development of clinical signs, including labored breathing or signs of a blood clot (paralysis, neurologic change).

PLAN

Reassess BP and treat if indicated. Consider consultation with an IM specialist if needed.

A recheck echocardiogram is recommended in 6 months to screen for any evidence of progression sooner if any clinical issues arise.

IMAGES



The information and recommendations provided are based on the images presented by the referring veterinarian. No evaluation can be communicated regarding pathology that was not visible in the image/video clips provided.

Thank you for this referral. This report was generated using transcription software, and minor dictation errors may be present. If the clinical or image interpretation does not parallel your findings or if I can be of any further assistance, please contact me.

Maggie Machen Lamy, DVM
Diplomate of the American College of Veterinary Internal Medicine (Cardiology)
info@sonopath.com